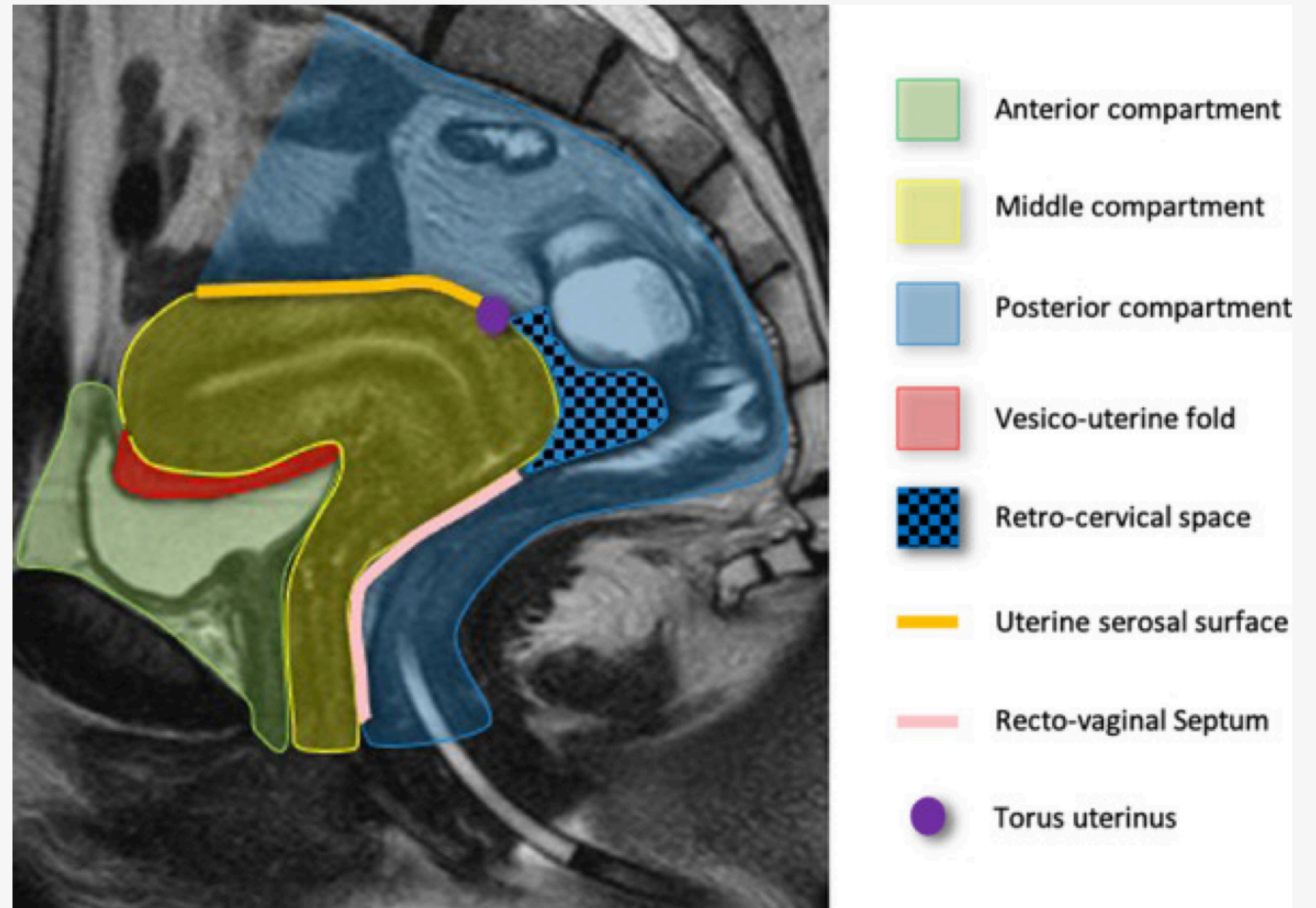


Diagnosis

Map Your Way

Owing to the complicated and unpredictable nature of the disease, it becomes doubly important for us to thoroughly map out the anatomy, and understand tissue presentation in MRI along various weightages and axis



Structured Radiology Report

01



Uterus

Version and Flexion (always mention)

Adenomyosis (if present)

04



Deep Implants

02



Adnexa

Location in the pelvis (always mention)

Are the ovaries tethered or displaced?

Endometrioma if present

Hydro or Hematosalpinx if present

03



Superficial Implants

Compartment and Location

Compartment and Location

Morphology (active glandular or stromal fibrotic)

Size of implant and space obliteration with surrounding organs

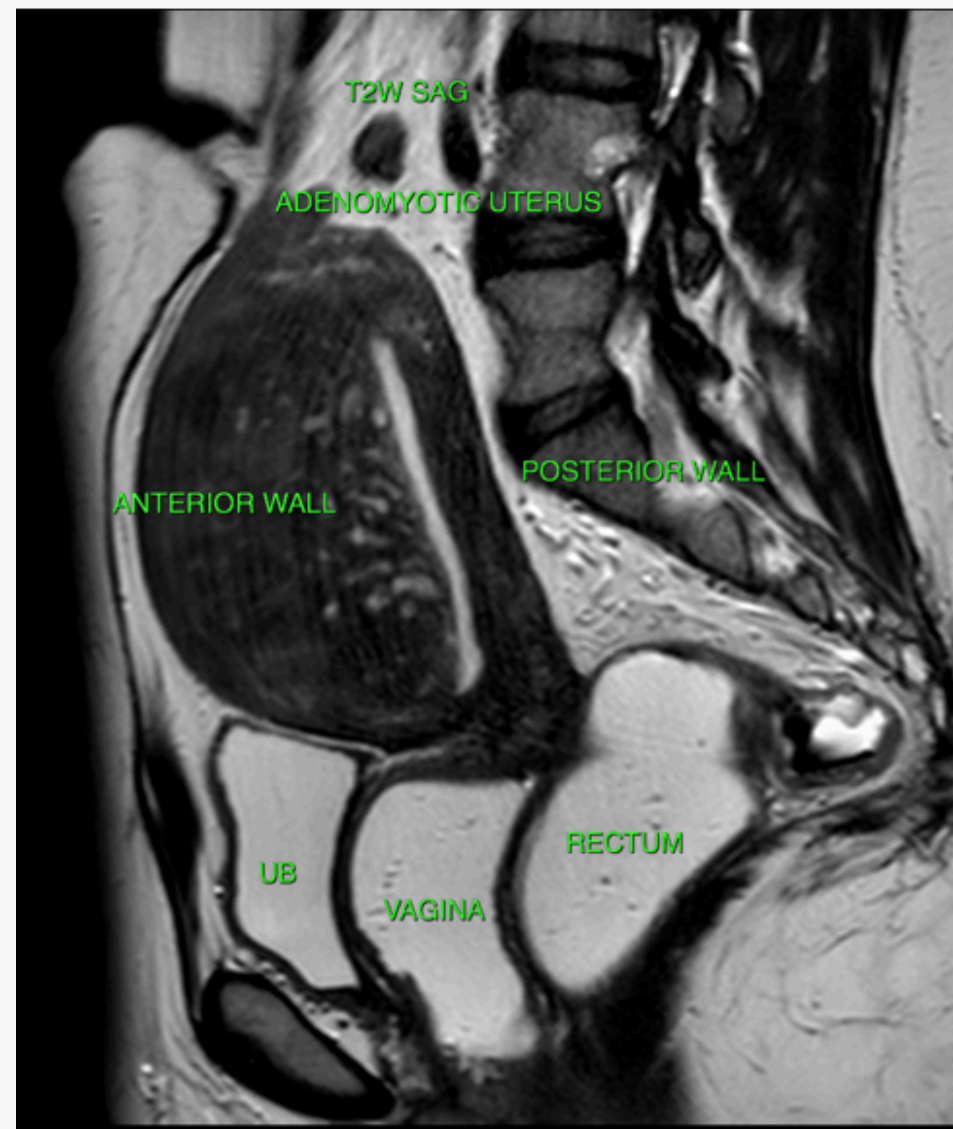
Organ invasion if present with individual organ detailing



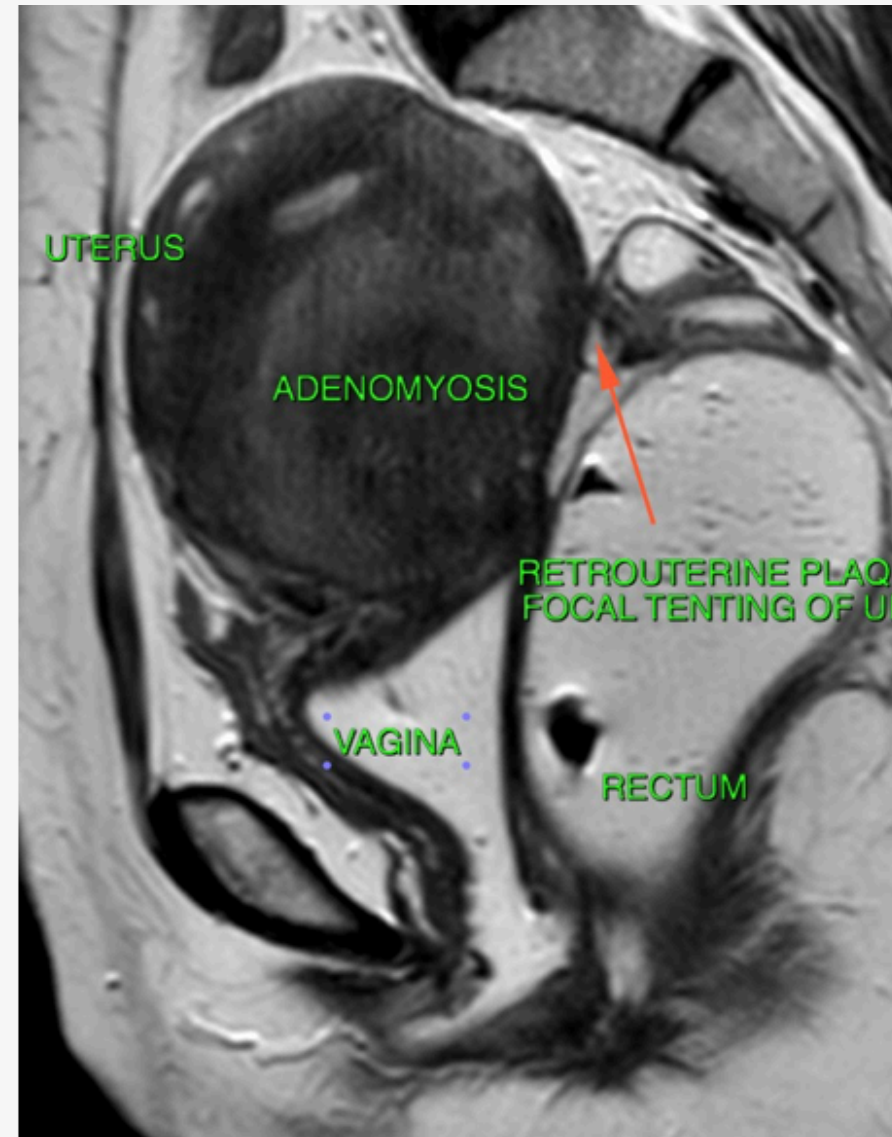
Patient Preparation

| | | | | |
|----|--------------------|---|------------------|---------------|
| 01 | Anti-Peristaltic | ↘ | Buscopan IV/IM | |
| 02 | Vaginal Distention | ↘ | USG Jelly ~50ml | |
| 03 | Rectal Distention | ↘ | USG Jelly ~150ml | Saline 750 ml |
| 04 | Bladder Distention | ↘ | Moderate | |

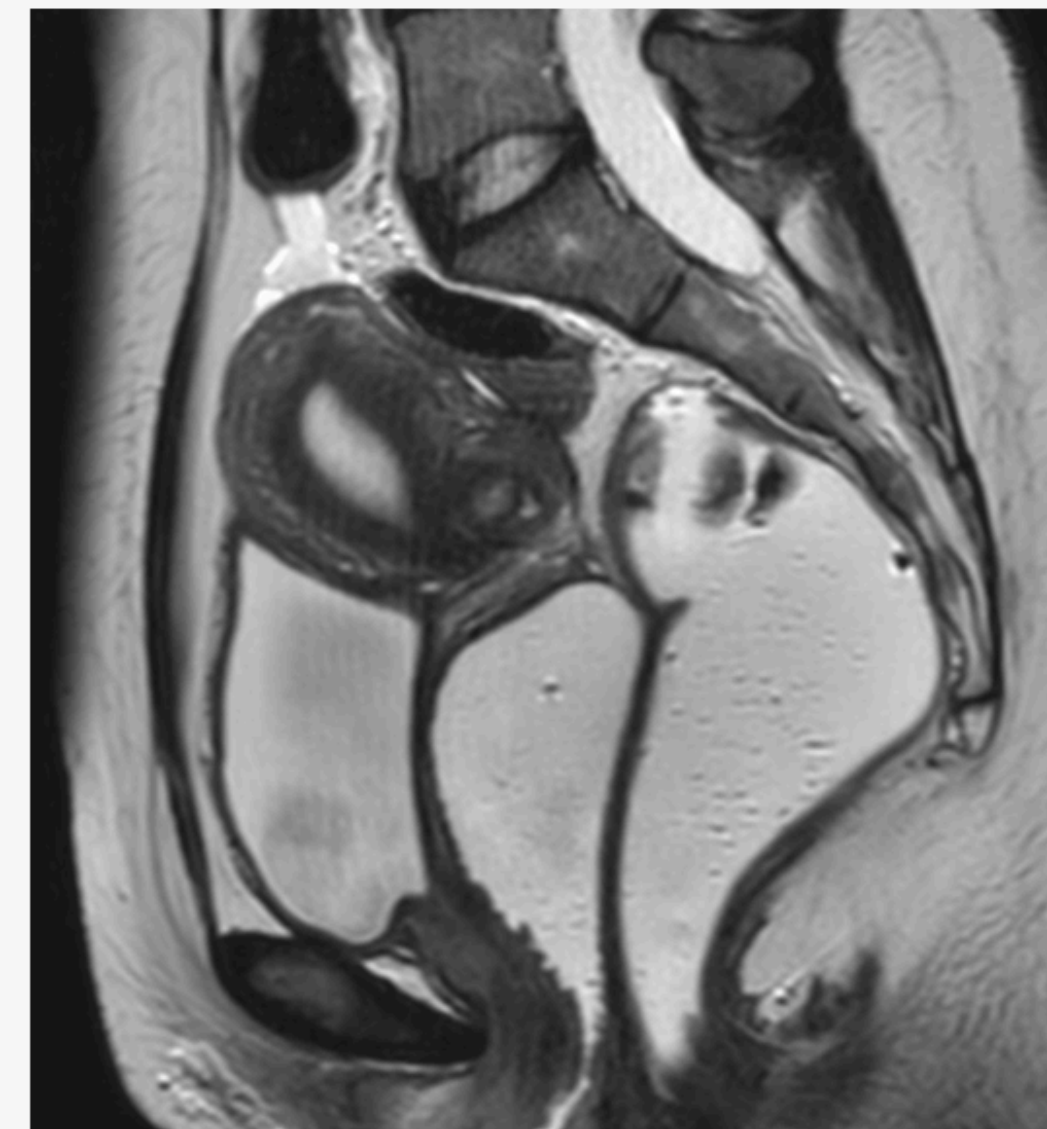
Adenomyosis



Focal



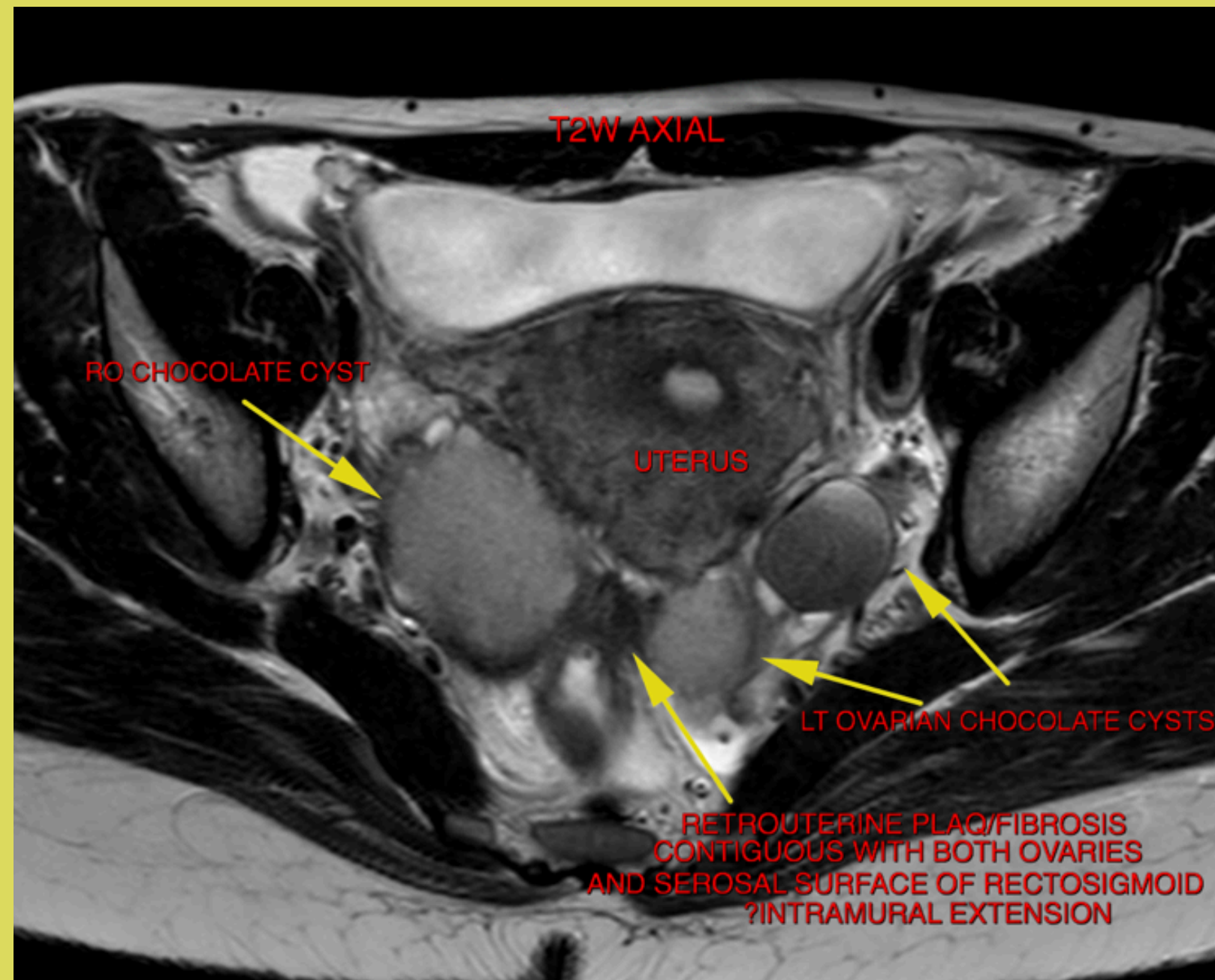
Diffuse



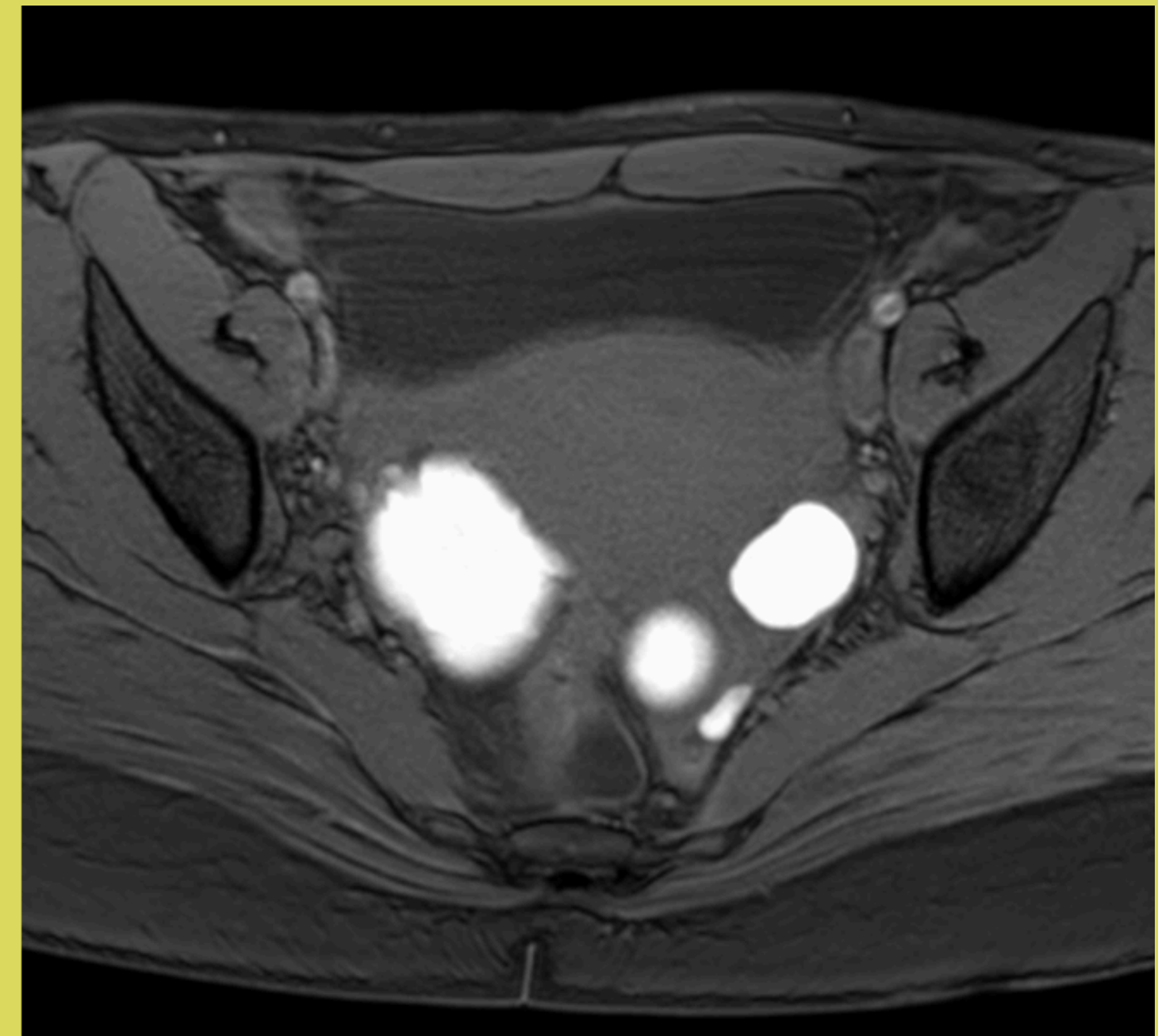Focal-Cystic

Mapping is of Paramount Importance

Endometrioma



T2W Axial



T1W Axial FS

Prevesical Space

Round Ligaments

Bladder

Distal Ureter

Cervico-Vesico-Uterine Pouch

Anterior Compartment

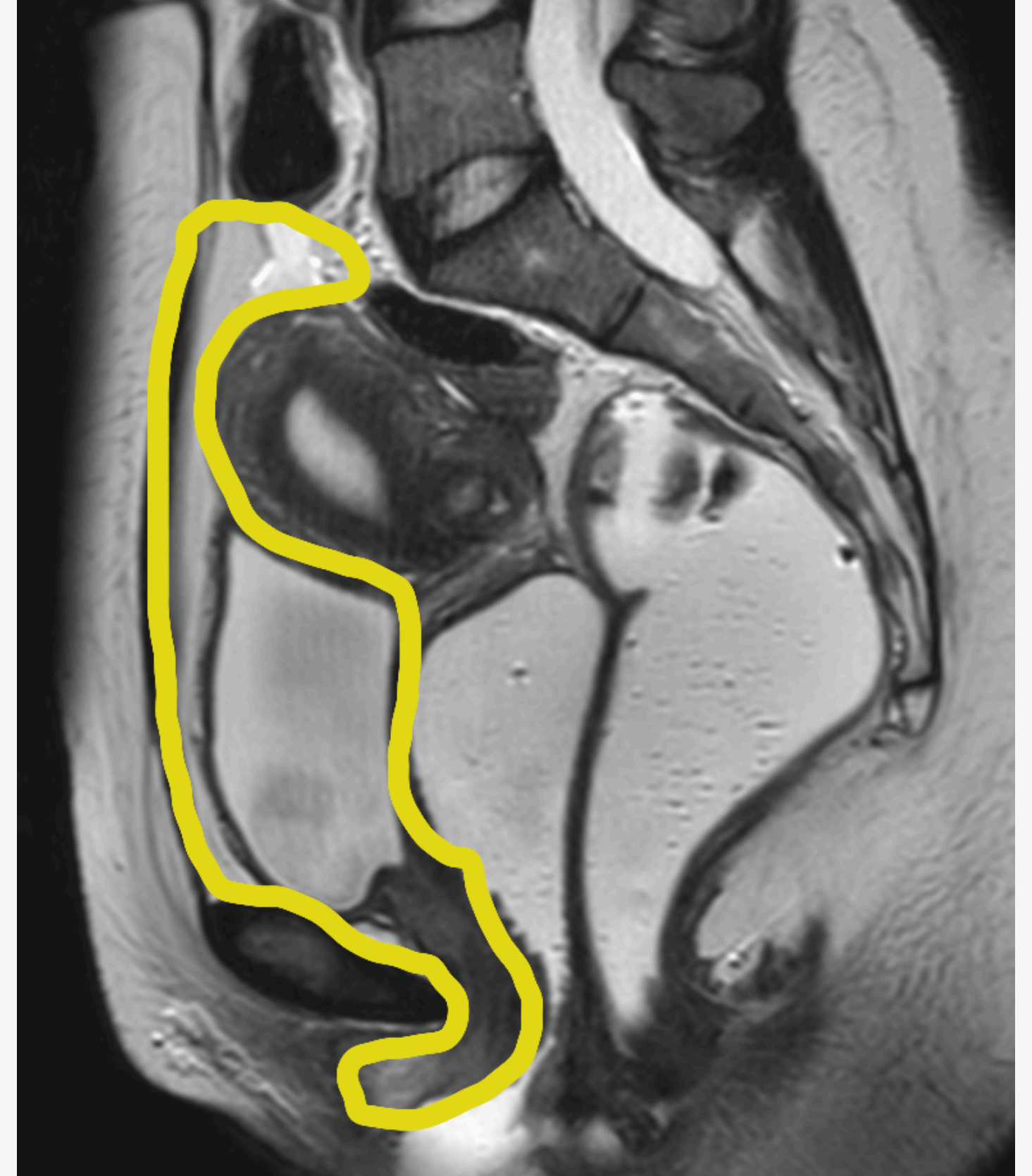


Image courtesy Medimax

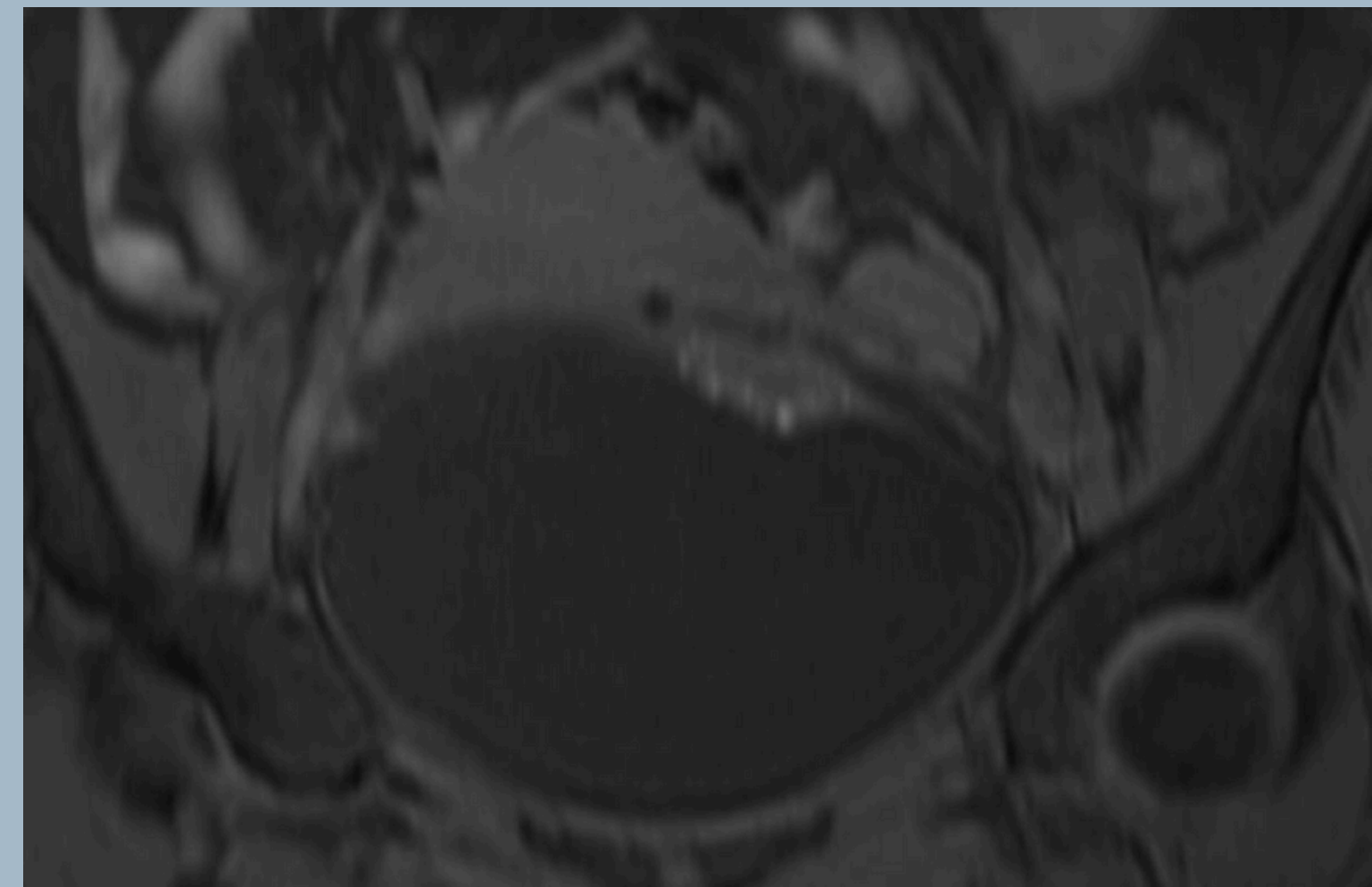
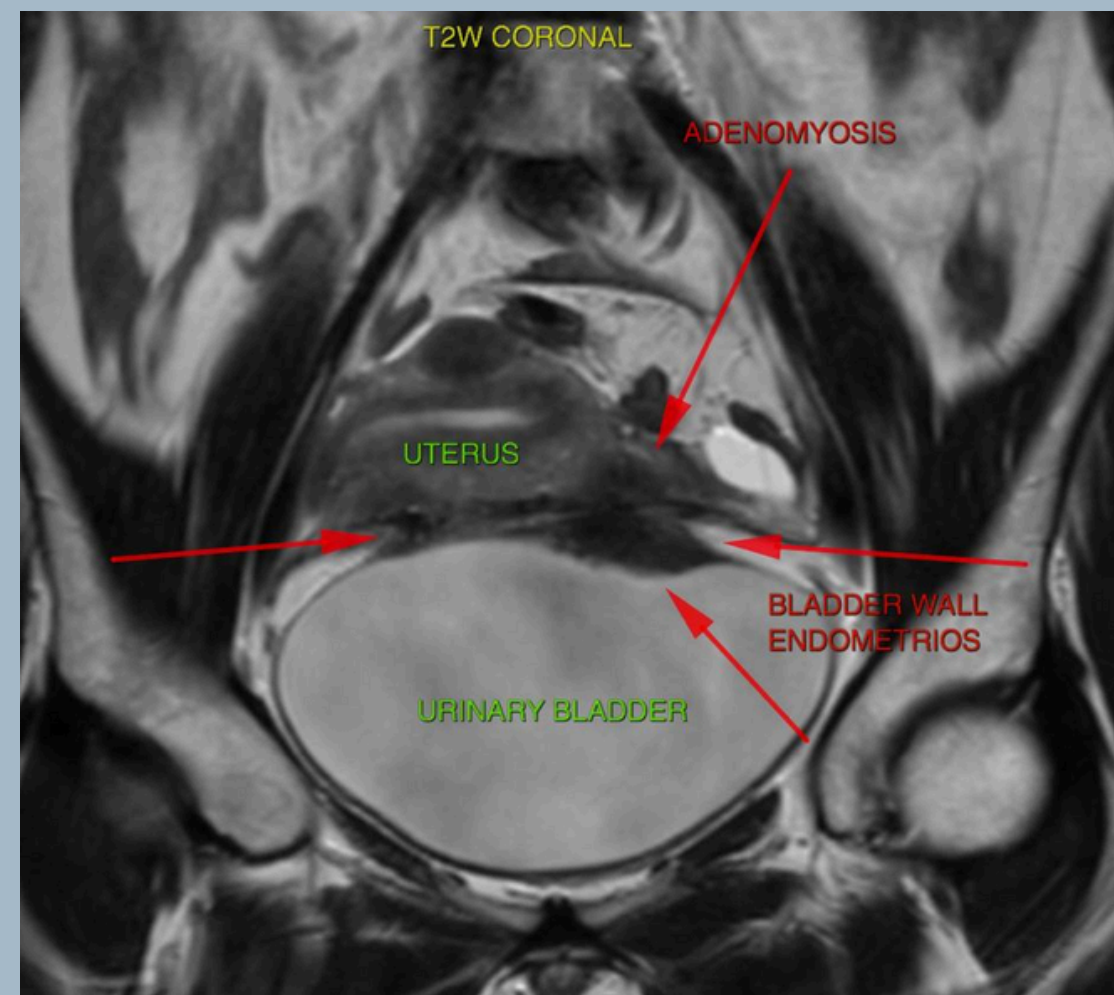
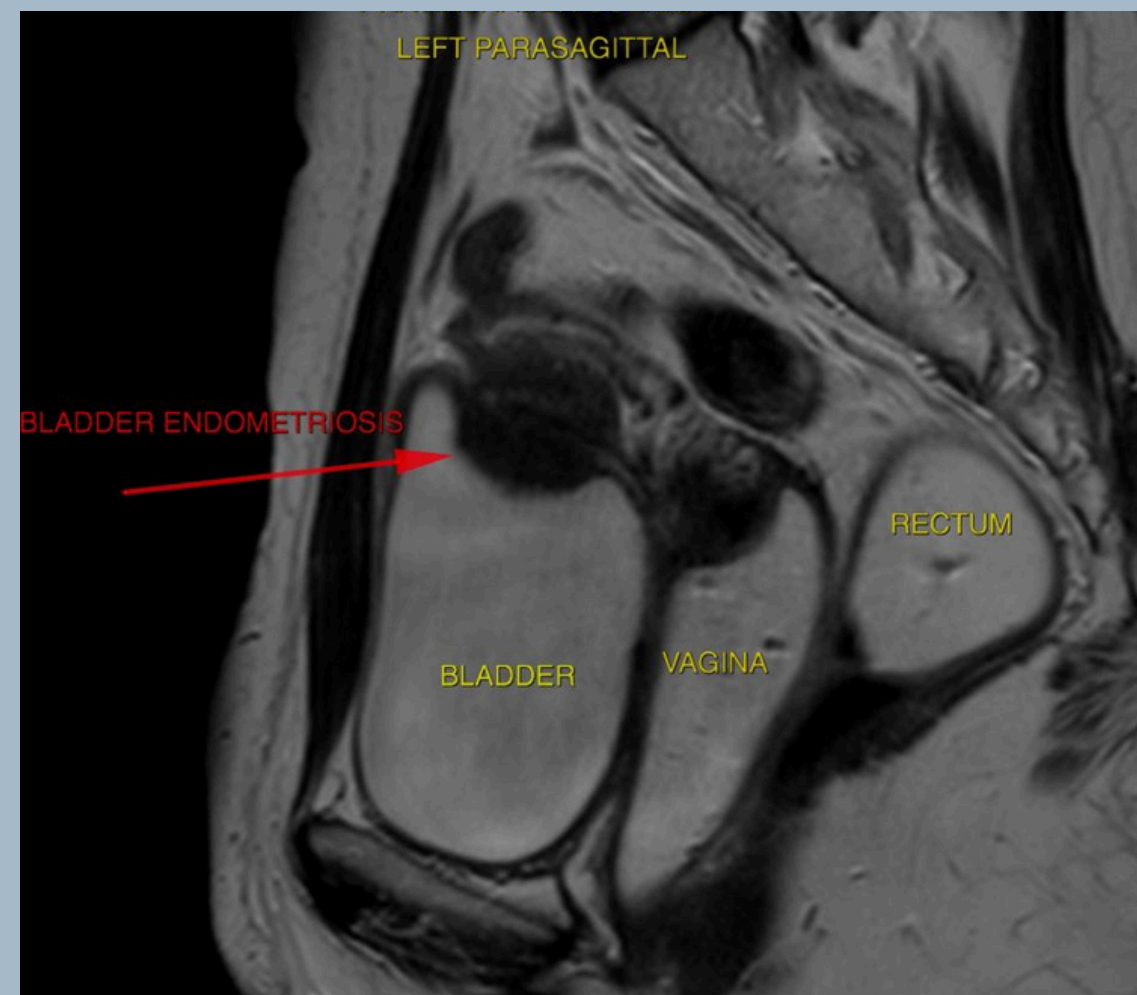


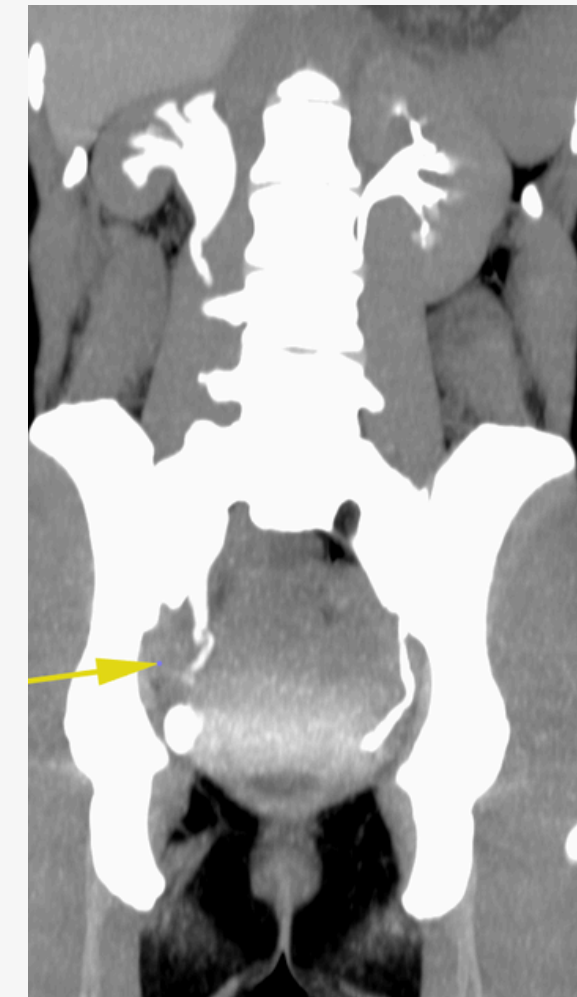
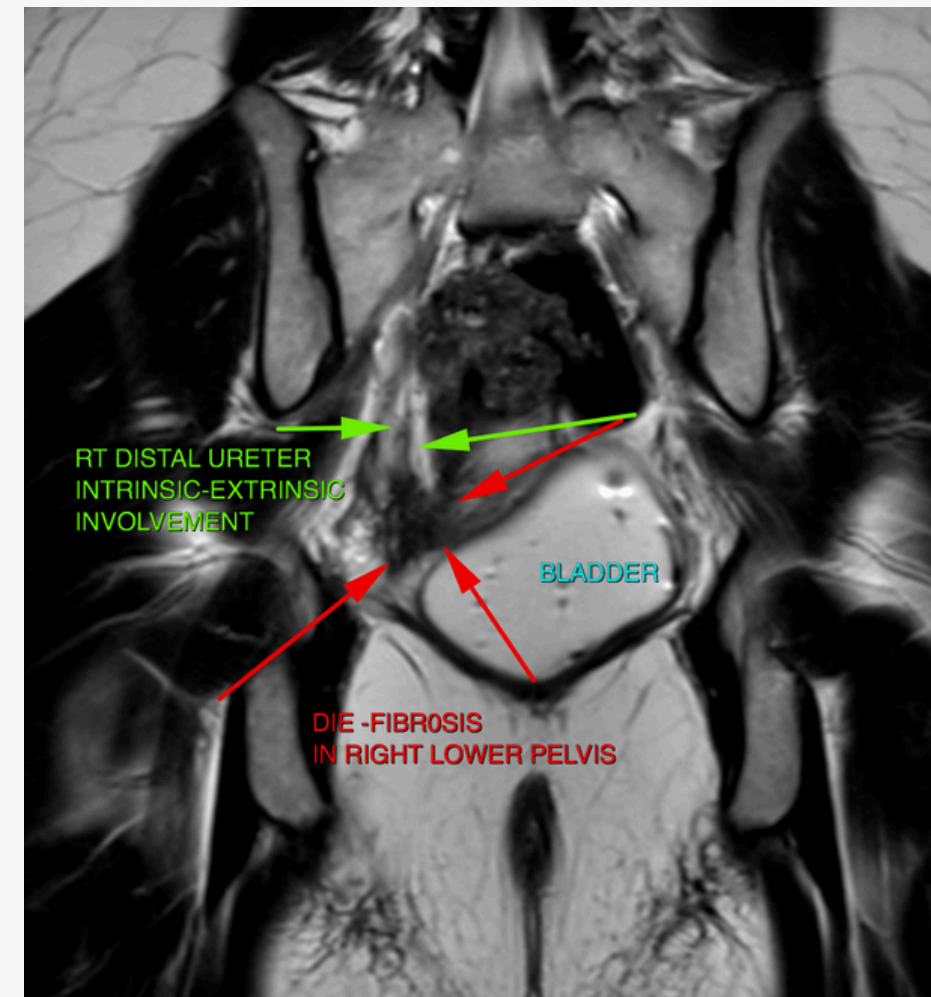
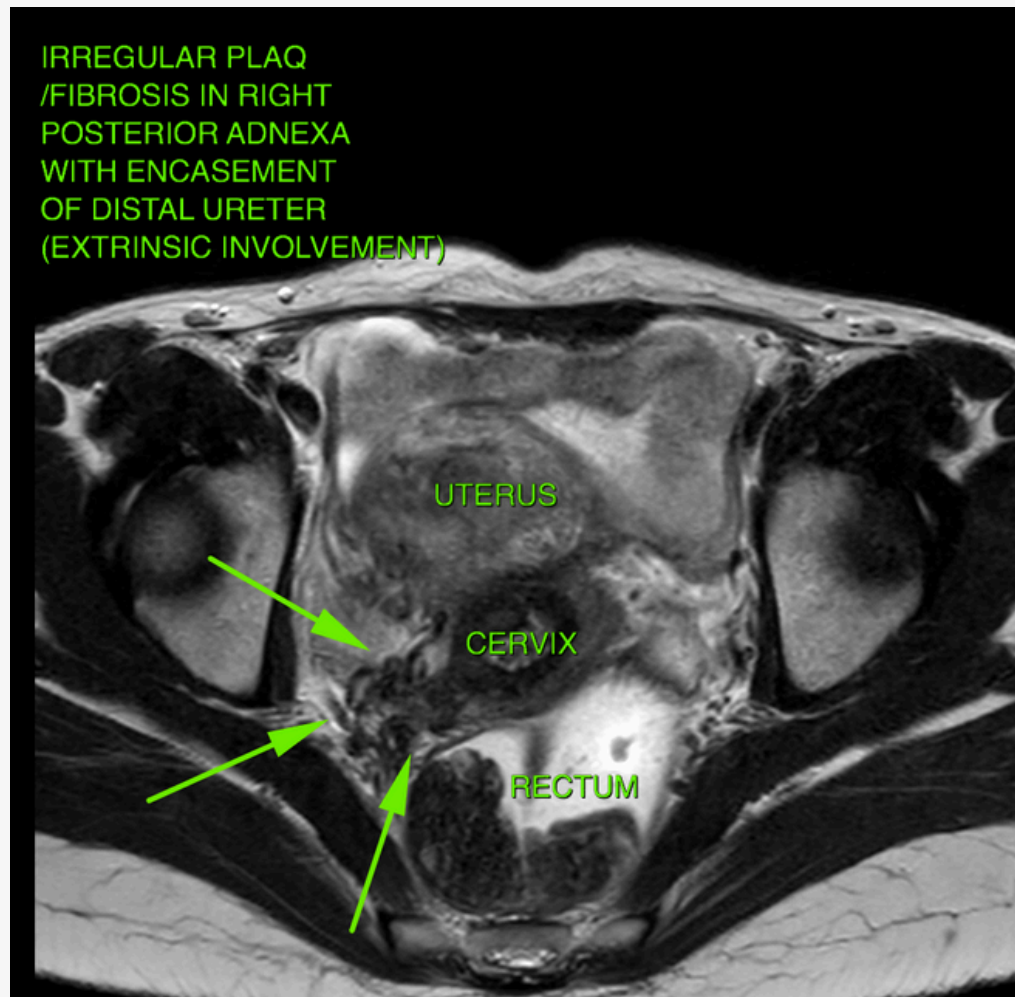
Image courtesy Medimax

Report should describe:

- Lesion Size and Location
- Depth of detrusor muscle invasion
- Distance from UVJ

Urinary Bladder

Two Subtypes - Extrinsic and Intrinsic



Report should describe:

Lesion size/length of ureter involved, extrinsic versus intrinsic subtype, absence or presence of hydroureteronephrosis & location and distance from UVJ along with the depth of invasion

Ureter

Vagina

Uterus

Fallopian Tubes

Broad Ligament

Ovaries

Middle Compartment

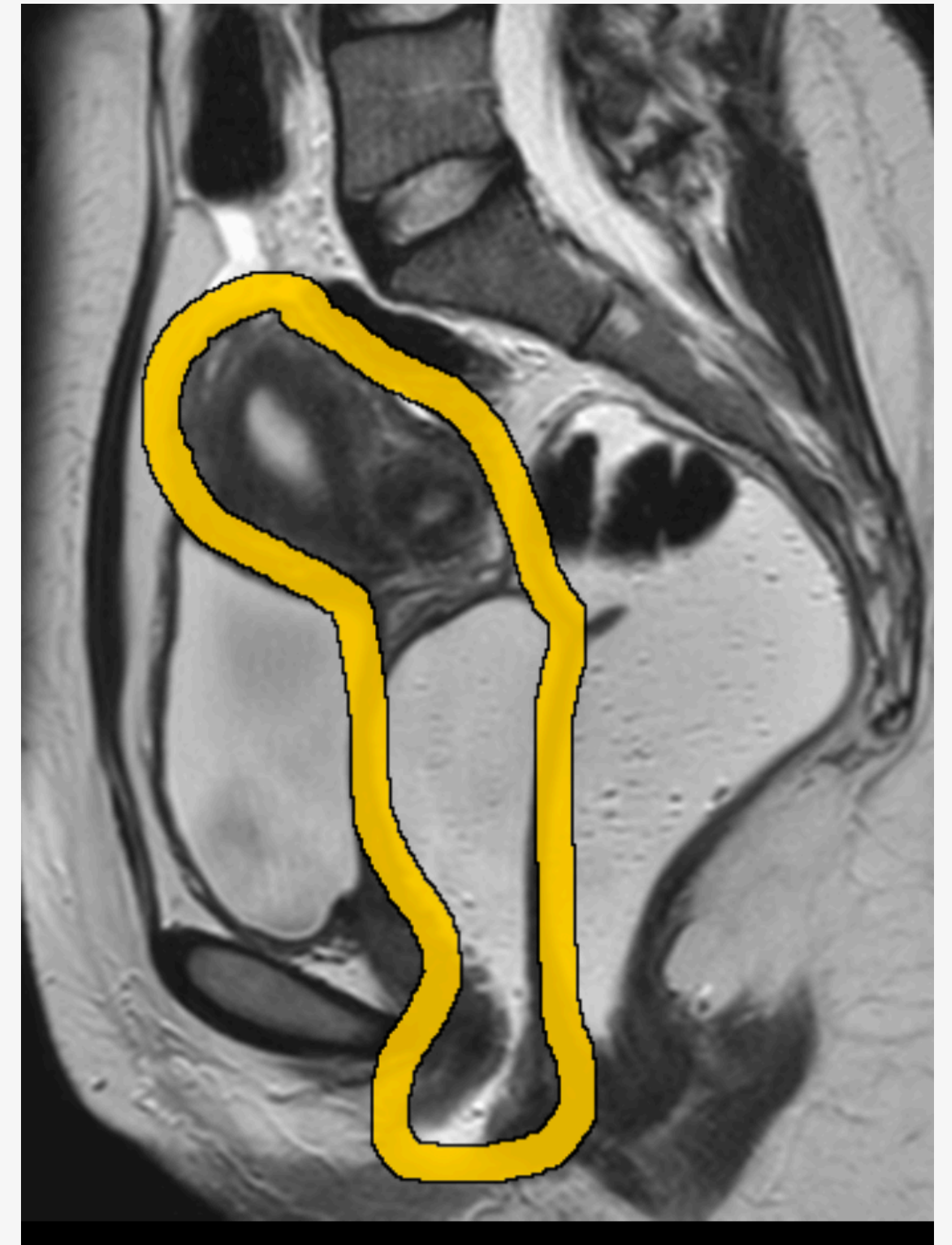

Image courtesy Medimax

Most often involves the posterior fornix.

Can appear as nodular thickening of the vaginal wall or as a polypoid mass extending into the lumen

Vagina

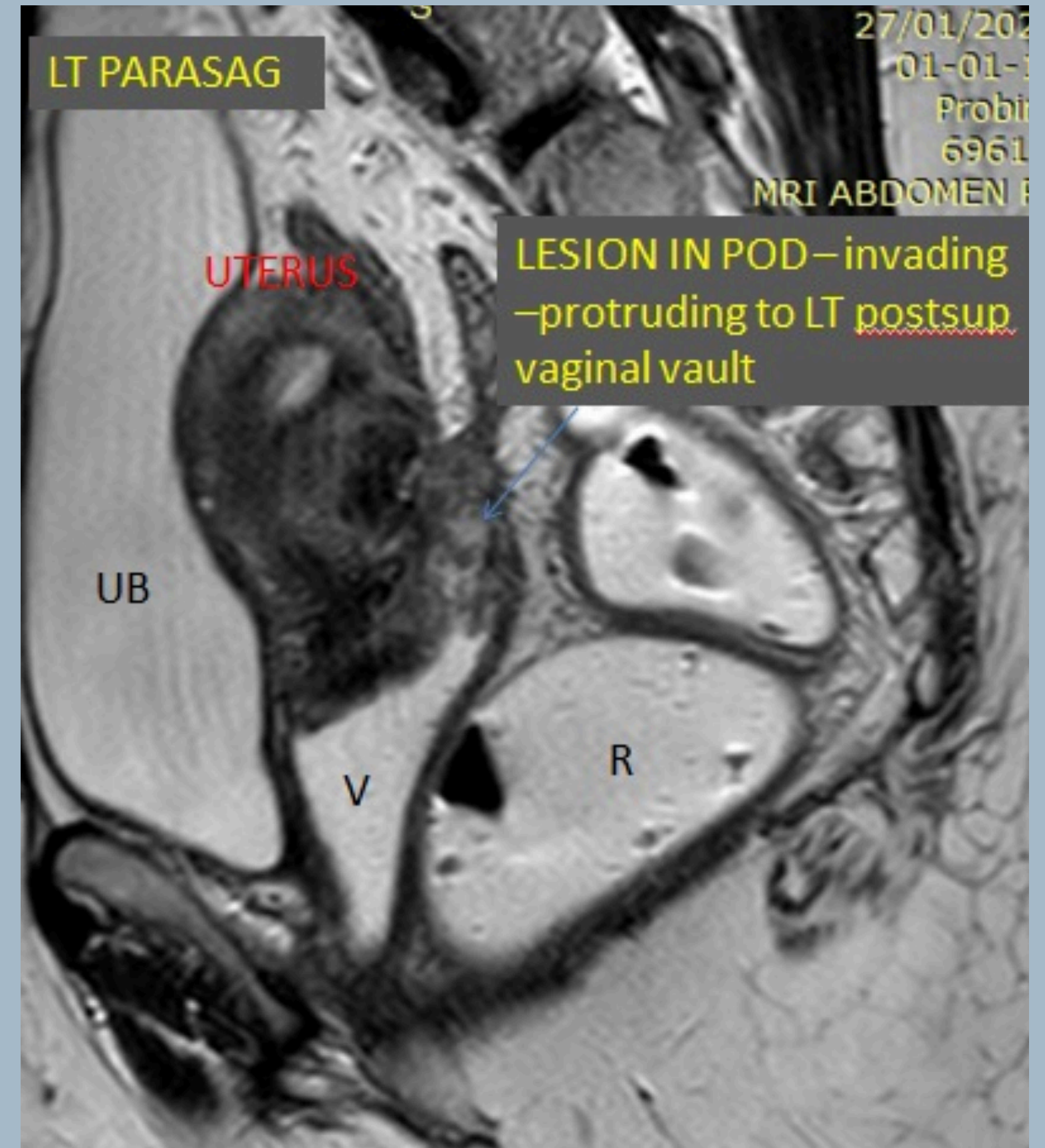


Image courtesy Medimax

Rectouterine and rectocervical space
Rectovaginal Septum and Pouch
Uterosacral Ligament
Rectum & Rectosigmoid Colon
Presacral Space

Posterior Compartment

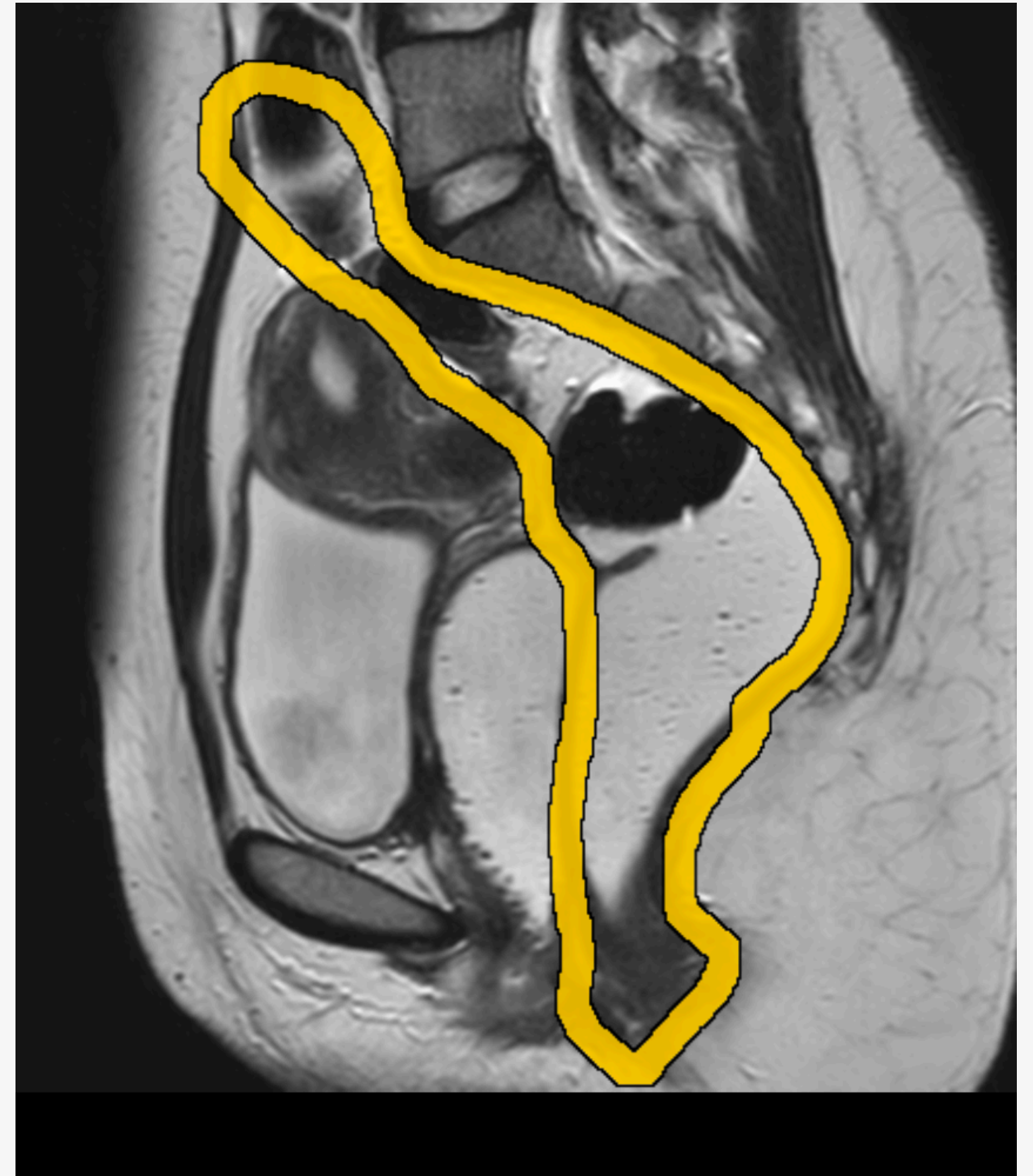
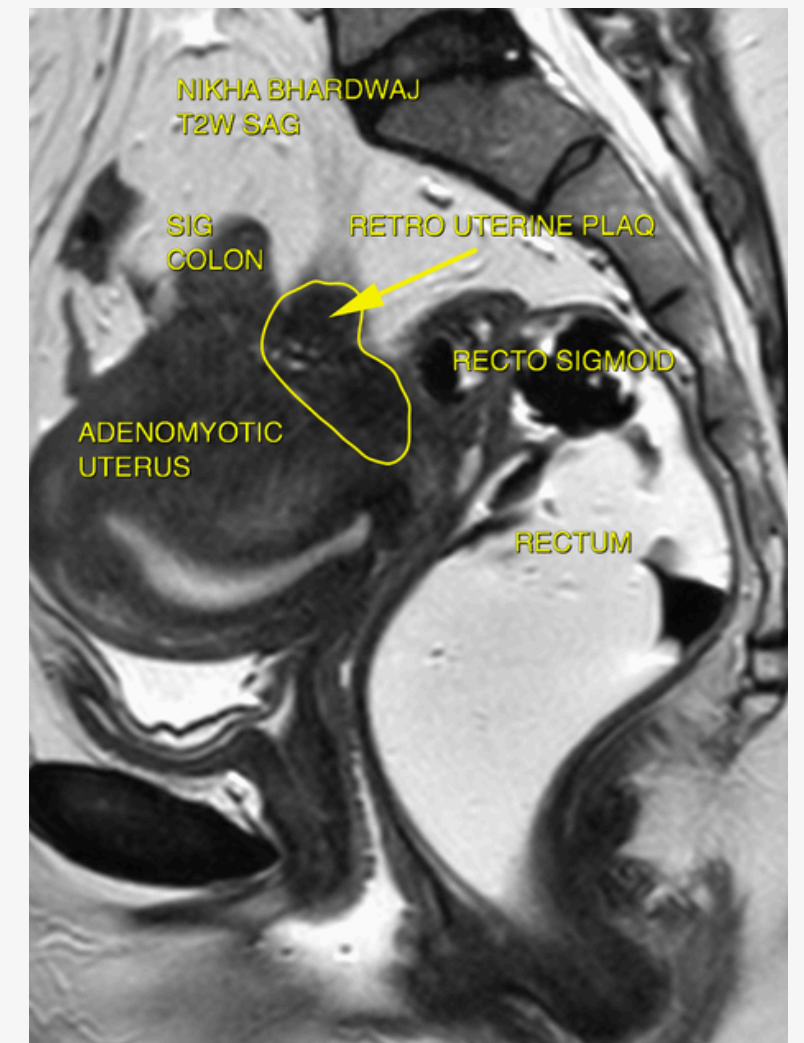
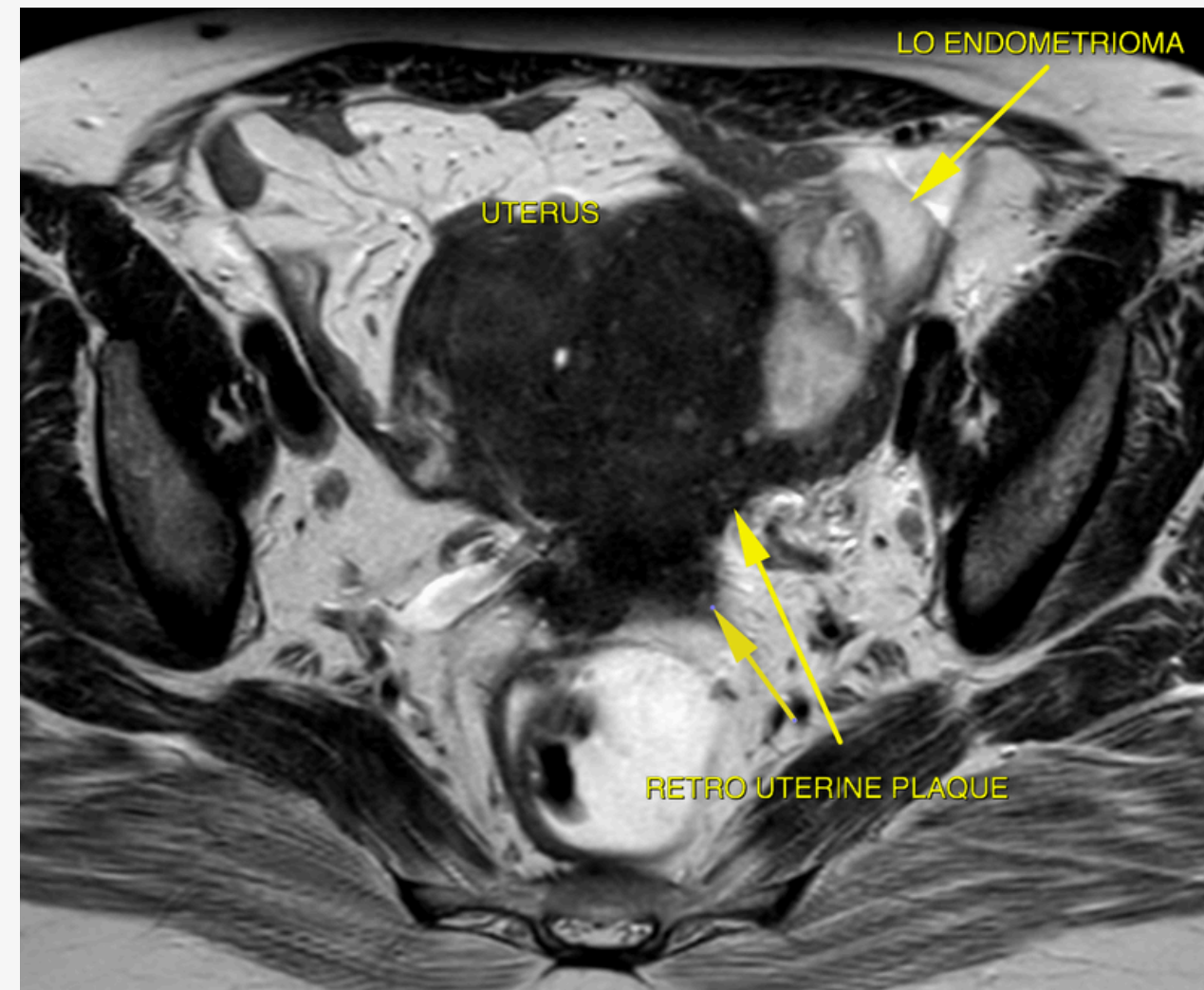
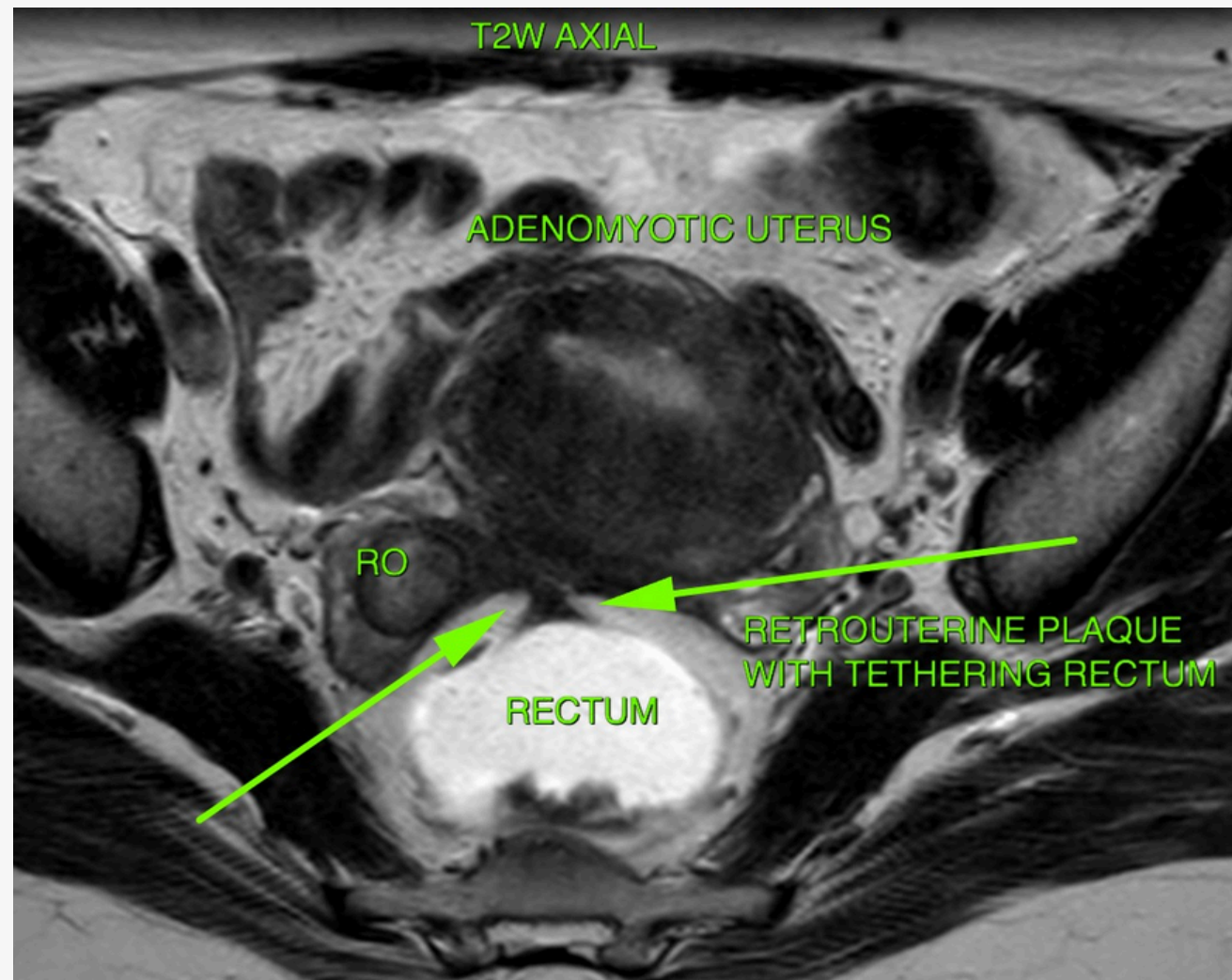


Image courtesy Medimax



Rectouterin / Cervical Space

Report should describe:

- Lesion size and location
- Depth of invasion
- % of circumference involved (in 3rds, or > or < 50%)
- Length of bowel involved
- Relationship to the peritoneal reflection
- Distance to anal verge

Bowel Involvement

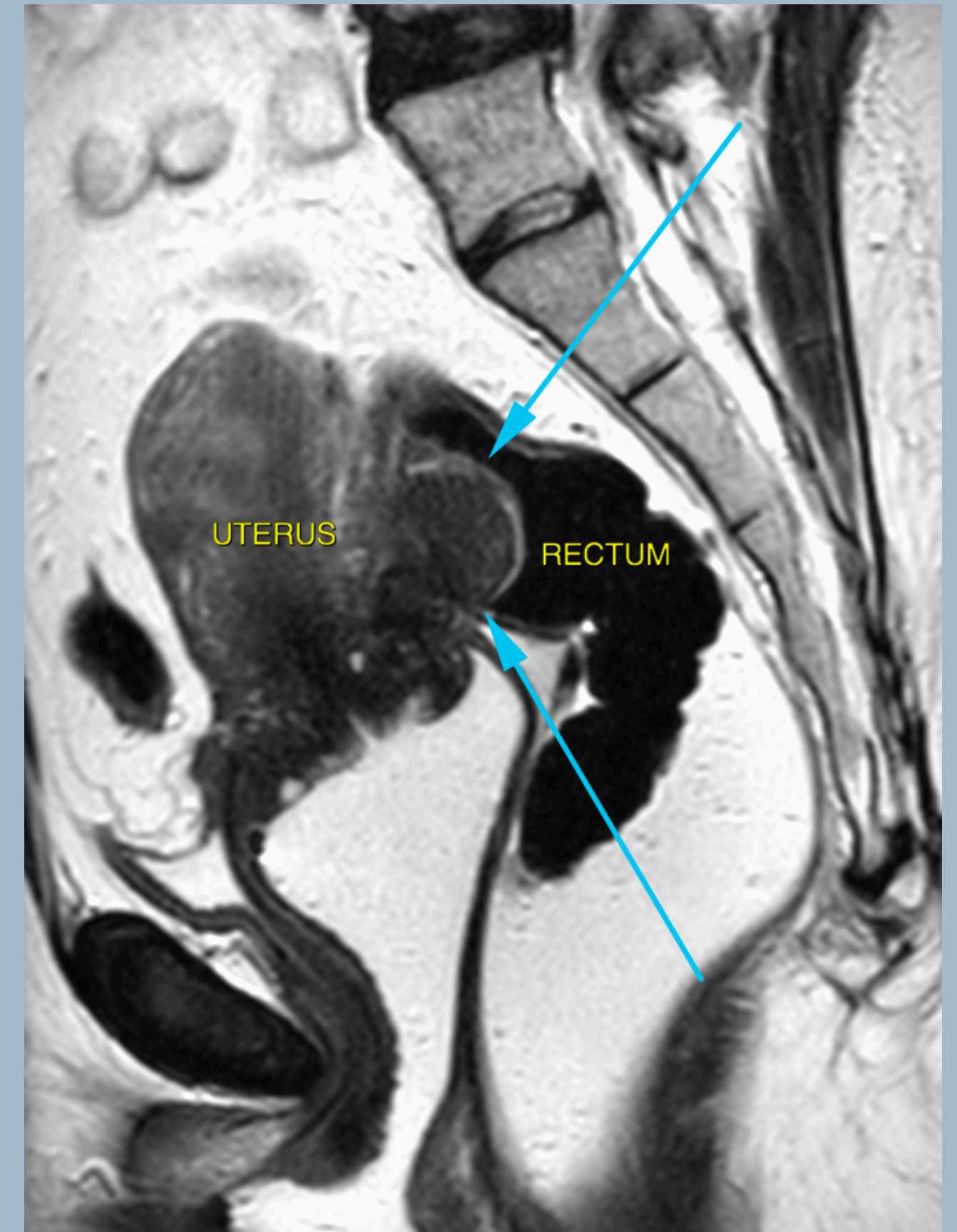


Image courtesy Medimax

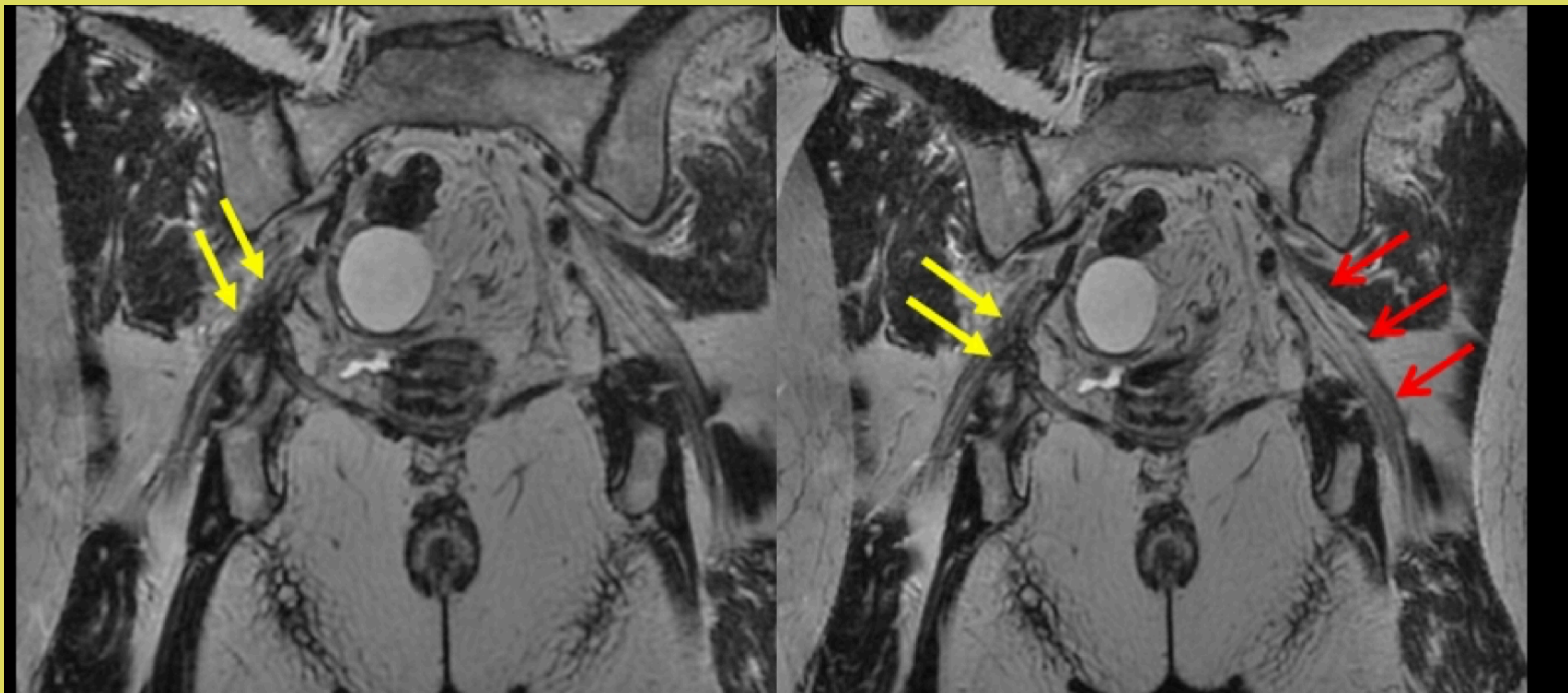
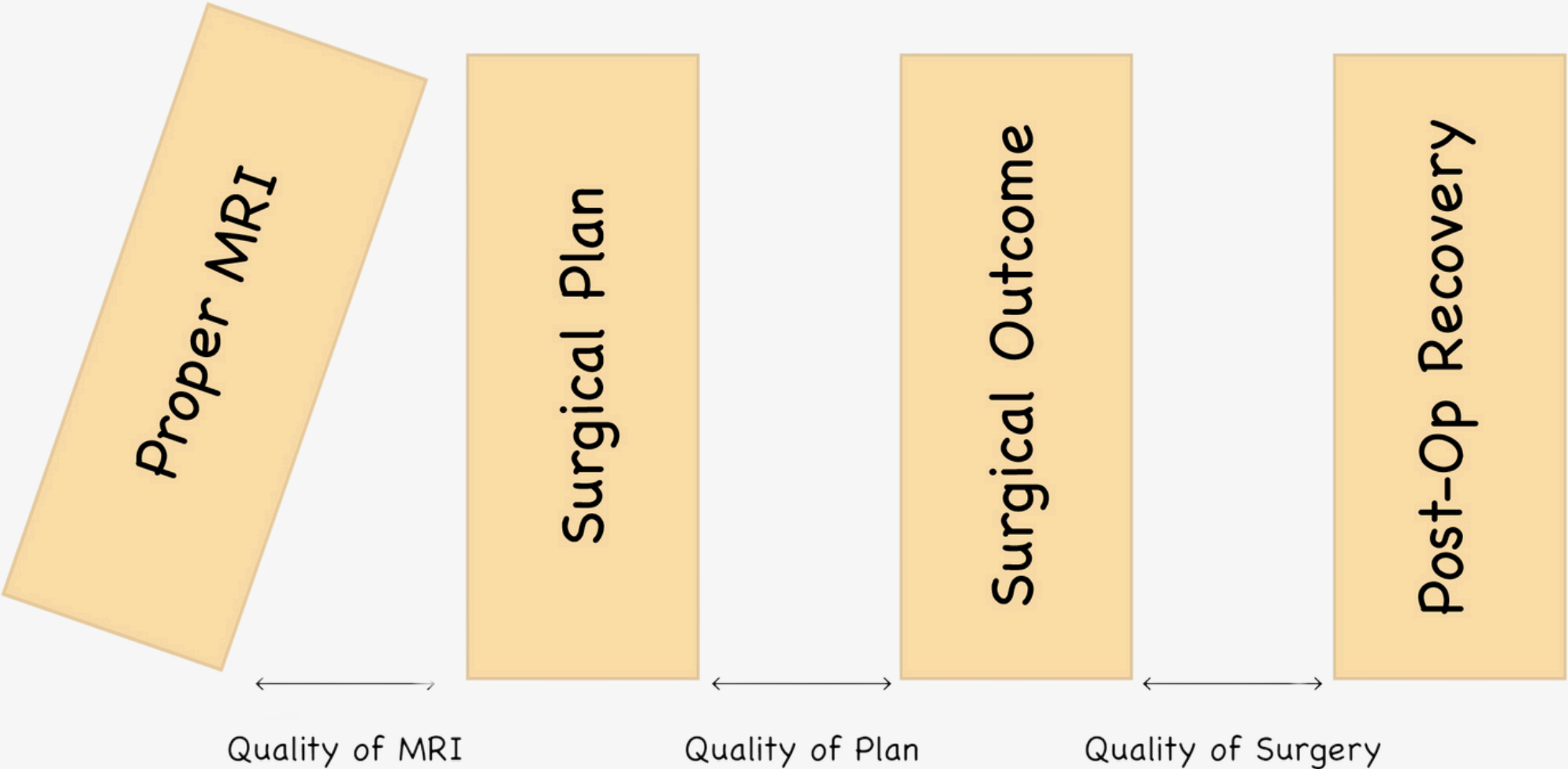



Image courtesy Medimax

Lumbosacral Trunk

The Surgery Domino



Subscribe to get smarter at managing Endometriosis
and your overall gynaec practice



pollen by *Mayflower*



 **Edometriosis Weekly**
by *Mayflower*

MRI reading service by Mayflower

Send us your MRI reports and get an in-depth mapping of the Endometriosis disease.

Elevate your surgical plan for positive patient outcomes.

Share the reports on: info@mayflowerhospital.com

